

CASE REPORT

## VAGINAL INSERTION OF ECTOPIC URETER DIAGNOSED IN ADULthood, THE FIRST CASE IN BOSNIA AND HERZEGOVINA

Emina Habibović<sup>1</sup>, Amar Habibović<sup>2</sup>, Samir Delibegović<sup>3</sup>

Received: 2 July 2021; Accepted: 10 January 2022.

### ABSTRACT

An ectopic ureter is defined as a ureter that does not insert into the normal anatomical position.

The occurrence of ectopic ureters is 1/2,000 in newborns and 1/2,000–4,000 in the general population. In most cases the ectopic ureter is associated with a duplicated renal collecting system, while in 20% a single system is found. The majority of cases are diagnosed during childhood as a result of continuous urinary dribbling or recurrent urinary tract infections.

In ectopic ureteral openings, diagnosis is often delayed because of inadequate evaluation;

in addition, most diagnostic methods do not provide sufficient information about ectopic ureteral openings.

In this particular case, we report on a patient with urinary incontinence and frequent episodes of urinary infections. In her childhood, she exhibited enuresis and was examined by a psychiatrist, followed by a neurologist and a gynecologist. CT urography revealed mainly hydronephrosis of the upper pole of the right kidney and a duplicate ureter on the right side, but not duplicate ureter insertion. Percutaneous nephrostomy was performed, with insertion of methylene blue into the collecting system. After the clinical investigation of the vagina with a speculum, a was observed blue dot at the vaginal fornix. Right partial upper pole nephrectomy and ureterectomy were performed.

An ectopic ureter opening is a clinical entity, rarely observed in a small country such as Bosnia and Herzegovina, but should be kept in mind during clinical evaluation of patients with incontinence, irrespective of the patient's age.

**Keywords:** ectopic ureter, vaginal, urinary incontinence, urinary tract infection, methylene blue

### INTRODUCTION

An ectopic ureter is defined as a ureter that does not insert into the normal anatomical position.

The occurrence of ectopic ureters is 1/2,000 in newborns and 1/2,000–4,000 in general population. The gender ratio is 2–6:1 in favor of females<sup>1</sup>. In most cases (80–85%) the ectopic ureter is associated with a duplicated renal collecting system, while in 20% a

<sup>1</sup> Urology Clinic, University Clinical Center Tuzla, Bosnia and Herzegovina

<sup>2</sup> Health Center of Tuzla, Tuzla, Bosnia and Herzegovina

<sup>3</sup> Clinic of Surgery, University Clinical Center Tuzla, Bosnia and Herzegovina

Emina Habibović

E-mail: [eminahabibovic5@gmail.com](mailto:eminahabibovic5@gmail.com)

Orcid ID: 0000-0002-8675-2013

single system is found<sup>2</sup>. The majority of these cases are diagnosed during childhood, as a result of continuous urinary dribbling or recurrent urinary tract infections (UTIs)<sup>3</sup>.

Clinically, it is seen 2–12 times more frequently in women, while in autopsy series the female/male ratio was found to be 2.9/1<sup>4</sup>. A small percentage (7.5–17%) of ectopic ureter cases are bilateral<sup>5</sup>. In men, it is usually accompanied by a single renal collecting system<sup>6</sup>.

In women, the urethra opens into the vestibulum and occasionally, but rarely, it can open into the vagina, cervix, uterus, Gartner's duct, urethral diverticle or rectum. Normal urination, together with continuous incontinence, are the pathognomic features of infraphincteric ureteral openings<sup>5</sup>.

In ectopic ureteral openings, diagnosis is often delayed because the majority of diagnostic methods do not provide sufficient information about ectopic ureteral openings, and there is no established protocol for this congenital anomaly<sup>2</sup>.

## CASE DESCRIPTION

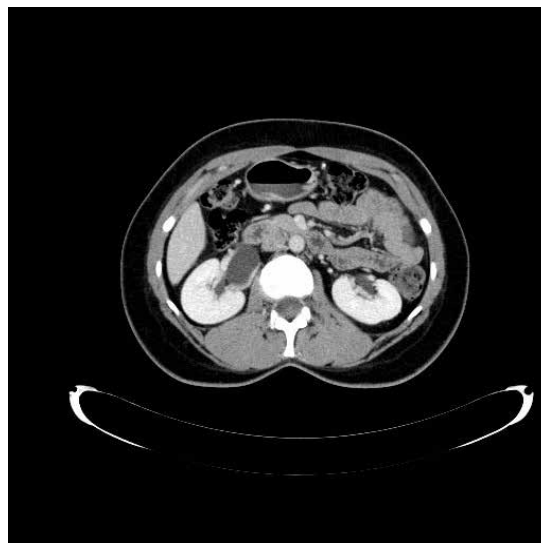
A 36-year-old-female was referred to our hospital (University Clinical Center, Tuzla) for investigation of urinary incontinence. She had continuous low volume urine leakage requiring 5 to 6 pads per day. Complete blood count, biochemical tests and urine analysis were normal, and two consecutive urine culture tests were negative.

In her childhood, the patient exhibited enuresis and was examined by a psychiatrist, followed by a neurologist and a gynecologist. There were no specific findings/diagnosis made. She had frequent episodes of urinary tract infections (up to 6 per year).

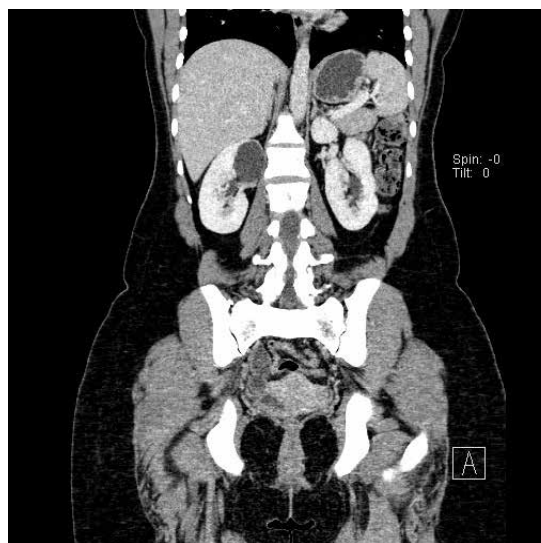
At the age of 28, she underwent urodynamic analysis that revealed slight detrusor hyperactivity, without the signs of stress urinary incontinence or residual urine. Cystoscopic findings were within normal range and she was prescribed a combination of Amzyol 3x10 mg and Tonocardin 1x1 mg therapy for

3 months, but this treatment did not result in any significant changes to her urinary leakage.

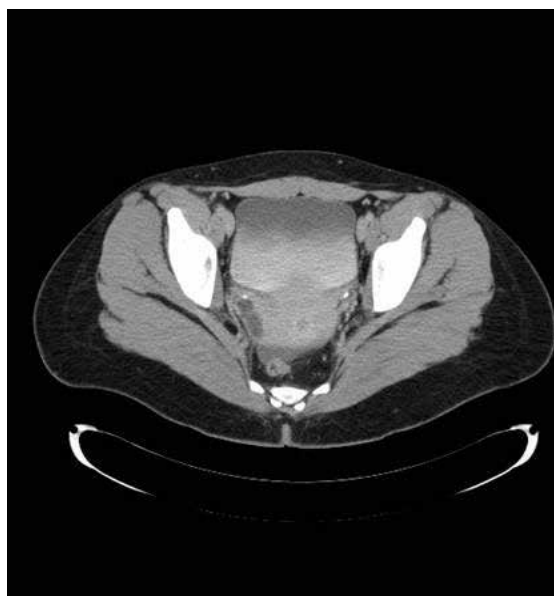
Ultrasonography showed a cortical cyst in the upper pole of the right kidney. This resulted in CT urography scanning. The images revealed important data about the entire collecting system and ureters, mainly hydronephrosis of the upper pole of the right kidney, and a duplicate ureter on the right side, one from the renal pelvis and the other from the upper pole (Figures 1-3).



**Figure 1.** Double ureters emerging from the renal pelvis.



**Figure 2.** Hydronephrosis of the upper pole of the right kidney.



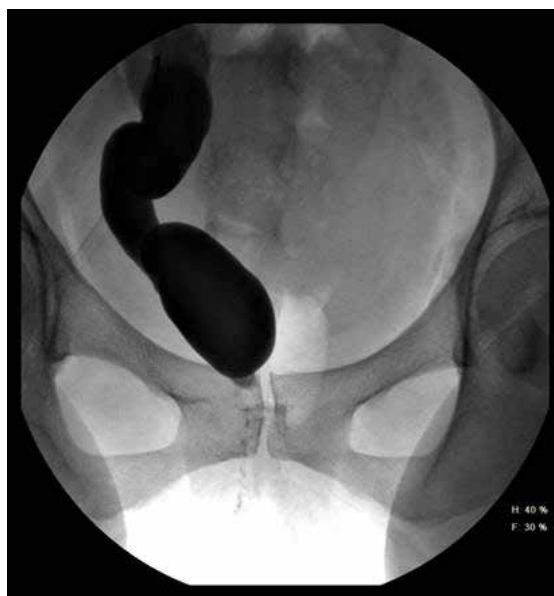**Figure 3.** Intrasphinteric urinary leakage shown by contrast CT urography (arrow).

However, CT urography did not reveal duplicate ureter insertion. This prompted us to perform percutaneous nephrostomy and insert contrast medium into the percutaneous nephrostomy system. This revealed ureterohydronephrosis and contrast urine leakage (Figure 4). There were no obvious ectopic ureteral openings, which led us to insert 20.0 ml of methylene blue into the collecting system. Following the methylene blue, upon investigation of the vagina with a speculum a blue dot was observed at the vaginal fornix (Figure 5).

Surgery was performed next: partial nephrectomy and ureterectomy in the right upper pole. There were no postoperative complications detected. Following the surgical treatment urine leakage completely ceased almost immediately. Furthermore, one month postoperatively, ultrasonography revealed that the right kidney exhibited no signs of hydronephrosis (Figure 6).

## Discussion

Even though ectopic ureter is a congenital anomaly, the diagnosis cannot generally be made before an advanced age because of inadequate anamnesis and



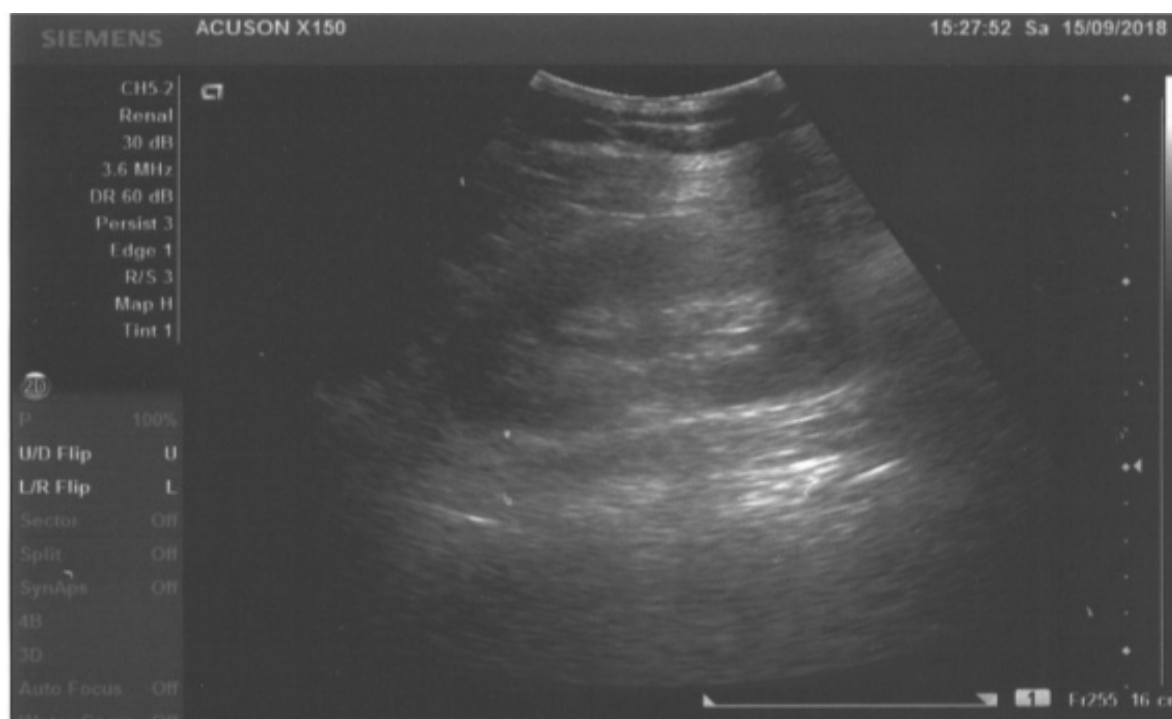
**Figure 4.** Urine leakage shown by contrast medium injection in the percutaneous nephrostomy system (arrow).



**Figure 5.** Vaginal ectopic ureter opening detected using methylene blue (clinical vaginal examination).

assessments<sup>7,8</sup>. This was the case with our particular patient as well, as she was not diagnosed until the age of forty years.

The presenting symptoms in the patient depend on the insertion site of the ectopic ureter, and this



**Figure 6.** Control ultrasonography of the right kidney, with no sign of hydronephrosis.

differs between girls and boys<sup>3</sup>. Usually, males do not present urinary incontinence because of the ureter's insertion above the external urinary sphincter, but they may present with antenatal hydronephrosis or urinary tract infections.

Most girls present with urinary dribbling, as the insertion of the ectopic ureter bypasses the exterior urinary sphincter. Usually, affected girls have normal voiding patterns with small volume leakage or spotting incontinence. In females, the most frequent sites of ectopic ureter insertion are the bladder neck and upper urethra (33%), the vaginal vestibule between the urethra and the vaginal opening (33%), the vagina (25%), and, less commonly, the cervix or uterus (<5%)<sup>3,9,10</sup>.

Only girls with a ureteral insertion at or above the bladder neck and upper urethra will be continent<sup>1</sup>. A single collecting system with an ectopic ureter is more frequently found in men, while in women the ectopic ureter is more commonly associated with a double collecting system<sup>6</sup>.

As the patient ages, other causes of urinary incontinence are predominantly contemplated, and eventually the diagnosis of ectopic ureter is overlooked<sup>11</sup>.

As in our patient, in the elderly, diagnosis of urge and/or stress type urinary incontinence was considered, and treatment planned accordingly. Many diagnostic tools were used for detection of urinary system anomalies.

According to Weigert-Meyer's law, ureter draining the lower pole should open more cranially, and become refluxive. However, in our patient the ureter draining the lower pole was in its normal position and non-refluxive. Regardless of all available diagnostic imaging, the value of methylen blue is significant and should not be underestimated as a diagnostic aid, especially in excretory type imaging studies. This method facilitates the confirmation of urinary tract junction obstructions, and visualization of hydronephrosis and hydroureter.

There is as yet no standardized protocol in place for diagnosing and treating these ectopic ureter

conditions. Our report suggests that in the diagnostic protocol, vaginal examination, followed by a cystoscopy and further imaging excretory type imaging studies with methylene blue instillation should be performed.

An ectopic ureter opening is a clinical entity, rarely seen in a small country such as Bosnia and Herzegovina, but should be kept in mind during clinical evaluation of patients with incontinence, irrespective of the patient's age.

### Conflicts of interest

The authors have no conflict of interest.

### References

1. Baskin Laurence S. Ectopic Ureter. Up to date (2016) Available online at: <http://www.uptodate.com/contents/ectopic-ureter>
2. Demir M, Çiftçi H, Kılıçarslan N, Gümüş K, Oğur M, Gülüm M and Yeni E. A case of an ectopic ureter with vaginal insertion diagnosed in adulthood. *Turk J Urol.* 2015;41:53-55. Published online 2014 Oct 15. doi: 10.5152/tud.2014.81567
3. Figueroa VH, Chavhan GB. Utility of MR urography in children suspected of having ectopic ureter. *Pediatr Radiol.* 2014;44:956. 10.1007/s00247-014-2905-4.
4. Fannin O, Cammack JT, Crotty KL, Neal DE. Bilateral single ectopic ureters: diagnosis using transrectal ultrasound. *J Urol.* 1993;150:1229-31.
5. Kibar Y, Avcı A, Akay O, Dayanc M. Dribbling of urine due to ectopic vaginal insertion of an upper pole ureter diagnosed by magnetic resonance urography. *Int Urol Nephrol.* 2005;37:695-7. <http://dx.doi.org/10.1007/s11255-005-0246-9>.
6. Avni EF, Matos C, Rypens F, Schulman CC. Ectopic vaginal insertion of an upper pole ureter: demonstration by special sequences of magnetic resonance imaging. *J Urol.* 1997;158:1931-2. [http://dx.doi.org/10.1016/S0022-5347\(01\)64183-1](http://dx.doi.org/10.1016/S0022-5347(01)64183-1).
7. Ogawa A, Kakizawa Y, Akaza H. Ectopic ureter passing through the external urethral sphincter: Report of a case. *J Urol.* 1976;116:109-10.
8. Toprak U, Erdoğan A, Paşaoğlu E, Karademir MA. The Importance of Pyelography Phase Computed Tomography in The Diagnosis of Ectopic Vaginal Ureter. *Ankara Üniversitesi Tıp Fakültesi Mecmuası.* 2007;60:35-7.
9. Nzenza TC, Rice G, Kinnear N, Hennessey D. An interesting case of lifelong urinary incontinence. *Austin J Urol.* 2016;3:1048.
10. Ghosh B, Shridhar K, Pal DK, Banerjee M. Ectopic ureter draining into the uterus. *Urol Ann.* 2016;8:105-7. 10.4103/0974-7796.171496
11. Meroğlu O, Zorlu F, Peker A, Duran H. Ectopic ureter: Case presentation. *Turkish Journal of Urology.* 1999;25:109-11.