

## REVIEW

# Complete Mesocolic Excision with Central Vascular Ligation during Laparoscopic Right Hemicolectomy: Technical Notes

Maria Michela Di Nuzzo<sup>1</sup>, Roberto Peltrini<sup>1</sup>, Luigi Vanni<sup>1</sup>, Michele D'Ambra<sup>1</sup>, Umberto Bracale<sup>1</sup>, Francesco Corcione<sup>1</sup>

Received: 2 April 2021; Accepted: 2 May 2021

## ABSTRACT

In this article we describe the surgical technique of the Complete Mesocolic Excision (CME) with Central Vascular Ligation (CVL) during laparoscopic right hemicolectomy (LRH) with intracorporeal anastomosis, as performed in our current surgical practice. The preparation of the patient, the operating room, the position of the surgeons, equipment and trocar placement are described in detail. The procedure is divided into well-defined steps, and each one is meticulously described.

**Keywords:** minimally invasive, laparoscopic right hemicolectomy, mesocolic excision, central vascular ligation

## INTRODUCTION

Several approaches have been described for right hemicolectomy: hand-assisted, laparoscopic assisted with extracorporeal anastomosis, totally laparoscopic with intracorporeal anastomosis, robotically assisted, and a single-incision approach<sup>1</sup>. COST<sup>2</sup> and COLOR<sup>3</sup> trials have proven the safety and efficacy of laparoscopic colectomy for treatment of colorectal cancer. The accuracy of oncological resection has an impact on cancer recurrence and survival. Since first described by Hohenberger<sup>4</sup> right hemicolectomy (LRH) with total mesocolon excision (CME) has been related to high oncological effectiveness, and results in a higher number of resected lymph nodes with the corresponding reduction in recurrence rates<sup>5</sup>. This complex procedure requires the central ligation of the vessels and the wide removal of the entire mesocolic tissue

that contains the regional lymphatic drainage, preserving the embryologic fascial envelope. Its complexity is related to the identification of the right mesenteric planes<sup>6</sup> and to the variability of the vascular anatomy<sup>7</sup>. In this article we describe our technique for LRH with CME and CVL associated with an intracorporeal anastomosis, as performed in our current surgical practice. Each step of our standard surgical laparoscopic technique is described as performed over thirty years of experience, with the support of 3D vision for facilitation of intracorporeal sutures<sup>8</sup>.

<sup>1</sup> Department of Public Health, University of Naples Federico II, Naples, Italy

Maria Michela Di Nuzzo

E-mail: mariamichela.dinuzzo@outlook.it

Orcid ID: 0000-0002-3000-3769

## SURGICAL TECHNIQUE

### Patient preparation

Patient preparation follows the ERAS protocol<sup>9</sup>. A Foley urethral catheter and a gastric nose tube are applied and are removed on the first post-operative day and at the end of surgery respectively. Antibiotic prophylaxis is carried out half an hour before skin cutting.

### Equipment

The equipment required for the laparoscopic right hemicolectomy with CME and CVL is shown in Table 1 with the respective quantities.

### Patient position

The patient is positioned supine on the operating table with the lower limbs placed on special stirrups that allow constant adjustment during surgery. The upper left limb is placed alongside the body. The patient is secured to the table with straps, and two shoulder pads are placed a few centimetres medially to the clavicular humeral joints and down to the level of the pelvis. Particular attention must be paid to anti-decubitus devices, given the different positions taken by the patient during surgery to facilitate the exposure of the operating field. The operating table must have the possibility of tilting both horizontally by up to 30°- 35° and vertically in the anti-Trendelenburg and Trendelenburg positions.

### Operating theatre set up

LHR requires a total of three surgeons: a first operator and two assistants, one scrub nurse and two operating room nurses. The operator and the first assistant (cameraman) take up positions to the left of the patient, the second assistant in the middle of the patient's spread legs, and the nurse on the right side of the patient in front of the surgeon operator. The laparoscopic tower with the monitor, the insufflator

and the camera are placed at the level of the patient's head on the right, if there is a possibility of a second laparoscopic tower, this is placed at the level of the patient's feet, always to the right. The generator for the ultrasonic scalpel and bipolar cladding are located to the left of the team.

### Location of trocars

A total of four trocars (T) are placed: T1(10-12 mm) in the periumbilical left region, usually 2 centimetres above and lateral to the navel; T2 (10-12 mm) in the left hypochondrium; T3 (5 mm) in the left lower quadrant; T4 (10-12 mm) in the left suprapubic region. T1 is used for optical access, T2 and T3 are the trocars for the operator surgeon, T4 is the assistant port. T1, T2 and T3 respect the concept of laparoscopy triangulation, T2-T3 are about 10 centimetres apart and about 8 centimetres from T1 (Figure 1).

### Pneumoperitoneum

Pneumoperitoneum is achieved using the Open Verres Assisted technique in the left upper abdominal quadrant with insufflation of 12-15 mmHg.

### Exploration

Once achieving the pneumoperitoneum, the first step consists of insertion of the T1 trocar, extracting the Verres needle and verifying the absence of iatrogenic lesions. Exploratory laparoscopy is the last diagnostic and the first operating stage. It is essentially undertaking an accurate exploration of the abdominal cavity for localization of the cancer and of any associated disease that can be treated during laparoscopy surgery.

### Identification of the ileocolic pedicle

The patient is rotated 30° to the left side and placed in slight Trendelenburg. In this way the small bowel moves to the left and the operator raises the omentum in the subdiaphragmatic region above the

Table 1: Equipment for laparoscopic right hemicolectomy wit CME

Equipment	Diameter	Quantities n
Need of Verres		1
Hasson	10-12 mm	1
Trocar	10-12 mm	2
Trocar	5 mm	1
Johann	5 mm	2
Delaitre	10 mm	1
Grasper	5 mm	1
Angled 30°laparoscopic lighting and insufflation	10 mm	1
Bipolar electrosurgical device	10 mm	1
Laparoscopic dissector	10 mm	1
Laparoscopic needle holders	10 mm	1
Endo surgical clips	10 mm	>1
End bag	15 mm	1
Rotulating laparoscopic linear stapler 60mm lenght	10-12 mm	>1
Suture (V-lock, Vicryl, riassorbibile monofilamente)		>1

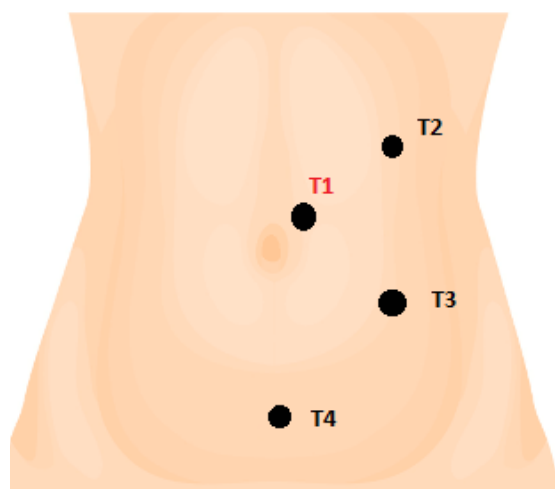


Figure 1: Trocars placement.

T1(10-12 mm) peraiombecal left region  
T2 (10-12 mm) left hypochondrium  
T3 (5 mm) left lower quadrant  
T4 (10-12 mm) left suprapubic region.

stomach in order to obtain better exposure of the operating field.

The last ileal loop is identified, the assistant places the ileocolic pedicle under tension, facilitating its identification by tractioning the ileocecal junction in a lateral direction. The incision of the peritoneum starts along the lower edge of the ileocolic vessels. The origin of the ileocolic vein and the superior mesenteric vein are completely exposed in this step (Figure 2).

### Vascular division and mesocolic dissection

The ileocolic vein and artery are dissected separately, ligated with surgical clips and divided by an energy device. The peritoneum is incised along the right edge of the upper mesenteric vein in a caudo-cranial direction so that the right colic vessels, if present, are ligated between clips and sectioned (Figure 3). The duodenum is identified and the medial to lateral approach allows the development of the 'mesocolic

window', the dissection is conducted along the embryological avascular plane between the Toldt's and the Gerota's fasciae with blunt maneuvers, so that the posterior mesocolic layer is separated by the retroperitoneal space (Figure 4). Continuing this dissection cranially, the lateral isolation of the duodenum is achieved, while medially the submesocolic area at the head of the pancreas is exposed. In a right hemicolectomy, the complexity of the anatomy is related to the mesenteric planes and to the anatomic variability of the tributary vein of the superior mesenteric vein<sup>7</sup>. At this level the correct identification is important of the right superior colic vein that can join the right gastroepiploic vein and the anterior superior pancreaticoduodenal vein, thus forming the gastroduodenal trunk (Figure 5). In the case of extending a right colectomy, the middle colic vein is sectioned at its origin. At each step, suspicious malignant central nodes are detected and removed to ensure oncological radicality.

### Hepatic flexure and ascending colon mobilization

Cranially, coloepiploic detachment allows the separation of the omentum from the transverse mesocolon (Figure 6). The hepatic flexure is mobilized by sectioning the peritoneal attachments and the previous surgical plane is found. The mobilization of the ascending colon is completed along the right colon gutter. The colon is sectioned by a linear stapler, through the suprapubic trocar in order to join the section site of the transverse colon perpendicularly, while the ileum is dissected to 10-15 centimeters upstream of the ileocecal valves with a white charged suture through T2, and the specimen is placed in an endobag for extraction.

### Intracorporeal anastomosis

The surgeon dissects the ileum with an Endo GIA white charge, and the colon with an Endo GIA blue charge. The surgical resection specimen is placed

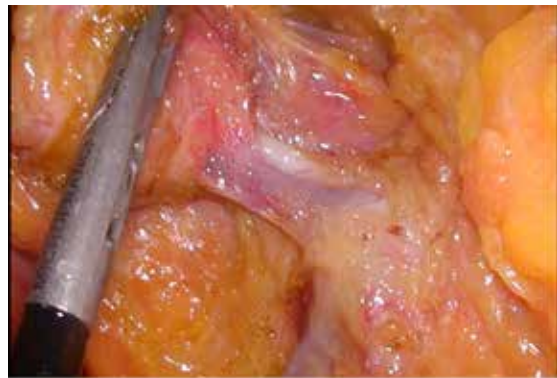


Figure 2. Ileocolic vessel identification.

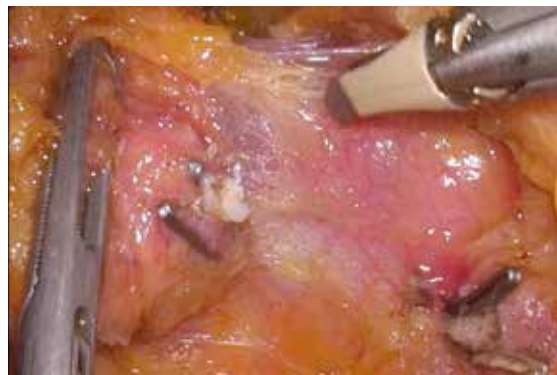

Figure 3. Ileocolic vessel section between clips.

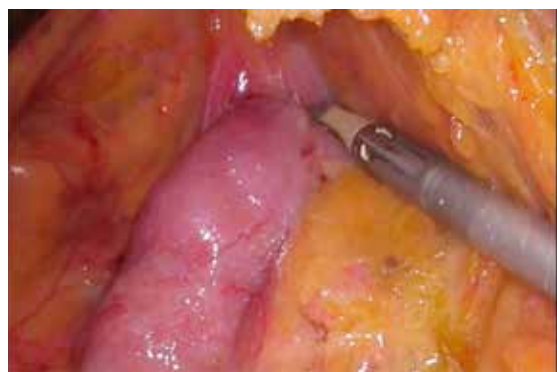

Figure 4. Toldt's and Gerota's fasciae dissection.

above the liver during intracorporeal anastomosis. The assistant lifts the extreme dissected colon and moves it to the right lateral abdominal wall while the operator moves the ileal stump to the transverse colon, evaluating the seat of the incisions for



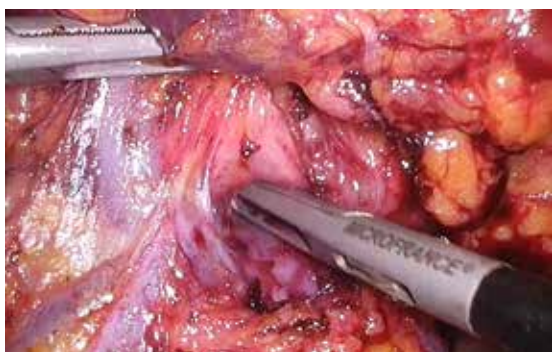

Figure 5: Henle trunk.

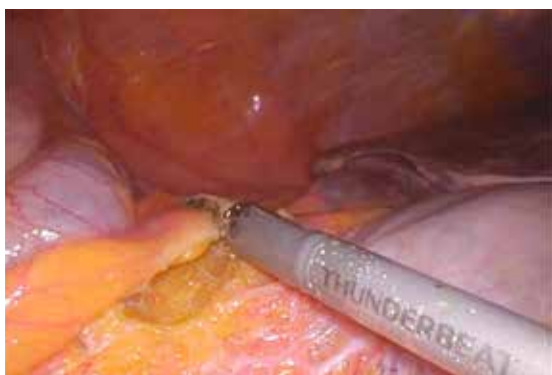

Figure 6: Coloepiploic medio-lateral detachment.

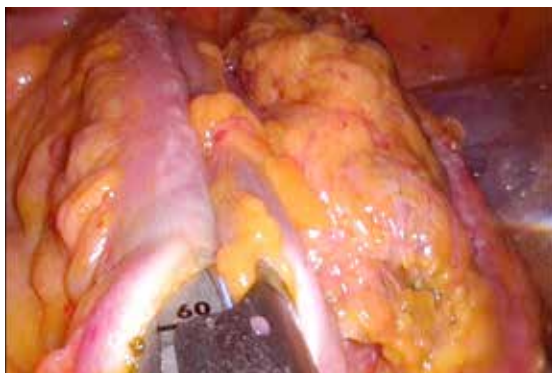

Figure 7: Intracorporeal anastomosis.

isoperistaltic side-to-side anastomosis. The surgeon performs enterotomy with the ultrasonic scalpel on the ileal wall, while at the colon level the incision is made at 6-7 centimetres from the stump. With the T2 trocar the operator introduces the 60 ENDO

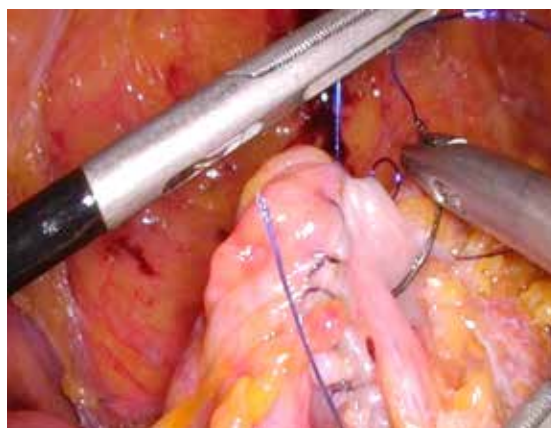


Figure 8: Double-Layer Closure technique.

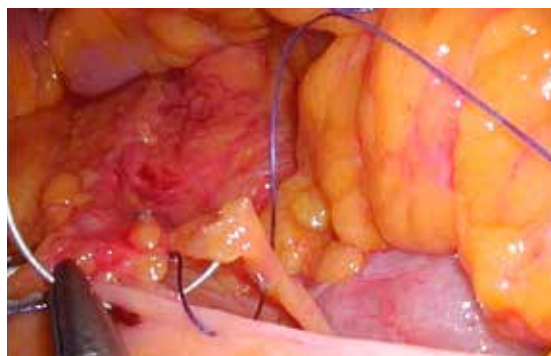

Figure 9: Intermesenteric suture.

GIA which is inserted into the enterotomy (Figure 7). Intracorporeal side-to-side isoperistaltic anastomosis is carried out, and the enterotomy is closed according to the Double-Layer Closure technique<sup>10</sup> (Figure 8). The intermesenteric space is sutured with stitches using Vicryl 3-0 to avoid internal hernias (Figure 9). The surgical resection specimen is extracted in an endo-bag by a Pfannestiel incision. No drainage is routinely placed, the nasogastric tube is removed at the end, and the urinary catheter on the first POD. A liquid diet begins the morning after the surgery. The patient is generally discharged on the fourth or fifth post-operative day.

### Conflicts of interest

The authors have no conflict of interest.

## REFERENCES

1. Gachabayov M, Bendl R, Latifi R, Bergamaschi R. Right Colon Resection: Evolution and Surgical Technique. *Surg Technol Int*. 2020;37:87-92.
2. Clinical Outcomes of Surgical Therapy Study Group, Nelson H, Sargent DJ, Wieand HS, Fleshman J, Anvari M, et al. A comparison of laparoscopically assisted and open colectomy for colon cancer. *N Engl J Med*. 2004;350:2050-9.
3. Colon Cancer Laparoscopic or Open Resection Study Group, Buunen M, Veldkamp R, Hop WC, Kuhry E, Jeekel J. Survival after laparoscopic surgery versus open surgery for colon cancer: long-term outcome of a randomised clinical trial. *Lancet Oncol*. 2009;10:44-52.
4. Hohenberger W, Weber K, Matzel K, Papadopoulos T, Merkel S. Standardized surgery for colonic cancer: complete mesocolic excision and central ligation - technical notes and outcome. *Colorectal Dis*. 2009;11:354-64.
5. Benz SR, Tannapfel A, Tam Y, Stricker I. Complete Mesocolic Excision for Right-Sided Colon Cancer - The Role of Central Lymph Nodes. *Zentralbl Chir*. 2015;140:449-52.
6. Peltrini R, D'Ambra M, Bartolini C, Lionetti R, Bracale U, Corcione F. Laparoscopic right hemicolectomy for cT4b caecal adenocarcinoma involving the bladder - a video vignette. *Colorectal Dis*. 2020;22:1771-1772.
7. Peltrini R, Luglio G, Pagano G, Sacco M, Sollazzo V, Bucci L. Gastrocolic trunk of Henle and its variants: review of the literature and clinical relevance in colectomy for right-sided colon cancer. *Surg Radiol Anat*. 2019;41:879-887.
8. Bracale U, Merola G, Rizzuto A, Pontecorvi E, Silvestri V, Pignata G, et al. Does a 3D laparoscopic approach improve surgical outcome of minimally invasive right colectomy? A retrospective case-control study. *Updates Surg*. 2020;72:445-451.
9. Pedrazzani C, Conti C, Mantovani G, Fernandes E, Turri G, Lazzarini E. Laparoscopic colorectal surgery and Enhanced Recovery After Surgery (ERAS) program: Experience with 200 cases from a single Italian center. *Medicine (Baltimore)*. 2018;97:e12137.
10. Bracale U, Merola G, Cabras F, Andreuccetti J, Corcione F, Pignata G. The Use of Barbed Suture for Intracorporeal Mechanical Anastomosis During a Totally Laparoscopic Right Colectomy: Is It Safe? A Retrospective Nonrandomized Comparative Multicenter Study. *Surg Innov*. 2018;25:267-273.